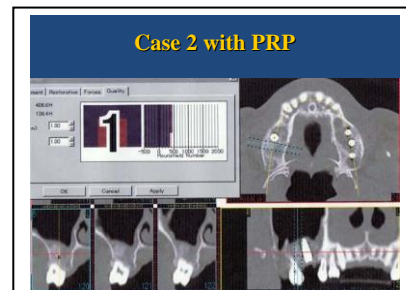
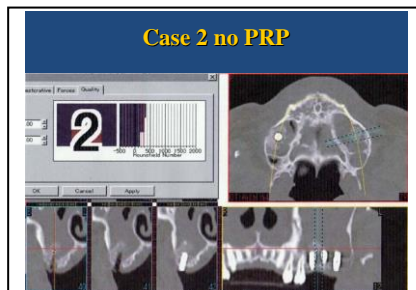
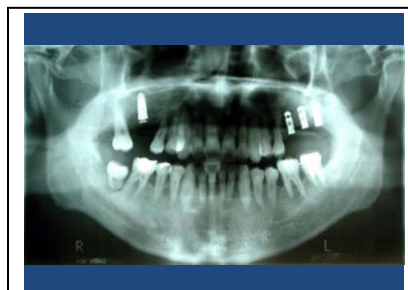

## It is PRP application and a non-application case of SINUS LIFT WITH VS With OUT

DR. HAJIME OKUDERA

Patient was a man, 44 years old, without a history of systemic diseases. The patient wanted implant treatment. There were 11 teeth (between 15 and 25, and 17) in the maxillae and 12 teeth (16-26) in the mandible. Tooth 17 was extracted for severe periodontitis.

Three months later, tooth 16 was extracted and another sinus lift operation was performed, this time placing PRP-containing bone materials in the space under the submucosal membrane of the maxillary sinus. Immediately after the operation, a Micro-vent implant (4.7 mm x 13 mm) was placed. Six months after the insertion of these fixtures, four Estenia® crown supported single standing implants were placed.



Conclusion :

Four months after the initiation of the trial, the CT value of tooth 16 was compared with that of tooth 26. It was found that the value on the right side, where PRP was used, was larger than the value on the left side (left:280, right:400). At present, the clinical outcome of the patient is good.

### Observation of Bone Augmentation Applied Platelet-Rich Plasma (PRP) to Different Implant Procedures

Purpose : The purpose of this study was to illustrate how the application of platelet-rich plasma (PRP) worked for alveolar bone augmentation in the patients receiving different modes of implant therapy, and to show the new technique, dental Aesthetics & Plastic Surgery case applying PRP.

Patients and Materials :

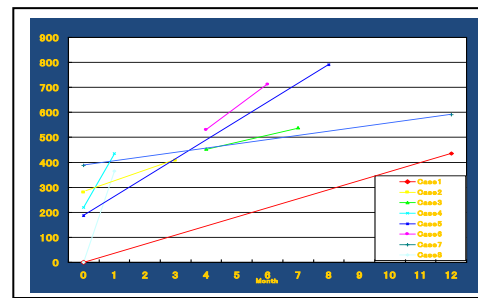
Biomaterials used in the implant treatment included resorbable hydroxyapatite (HA, Ostogen™), demineralized freeze-dried bone allografts (Deanbone) and bone harvest from the tibiae and four types of implant material. PRP was prepared by extracting blood of 60 ml from the patient and using the Smart PRP™ (Harvest Tec, U.S.) device to sequester and concentrate platelets.

The PRP was mixed with 5,000 units of thrombin (Mochida Pharmaceutical, Japan) and HA, and autologous bone chips collected at the time of drilling were added to the mixture to make bone regeneration materials in the form of a gel. PRP gel was used for all patients in this study during implant surgery. Prior to the operation and during the follow-up, computerized tomography, and dental and panoramic radiography were performed. CT images were analyzed by means of SIM/Plant. The patients gave informed consent about this clinical trial.

Case			
Case 1	Male, 36y	Upper Left 25 26	Sinus Lift & HA Coated Implant
Case 2	Male, 44y	Upper Right, 16 Left, 26	Sinus Lift & HA Coated Implant
Case 3	Male, 42y	Upper, Right 13	GBR
Case 4	Female, 39y	Upper, Right 13	GBR
Case 5	Female, 69y	Upper, Left, 26	GBR
Case 6	Female, 39y	Upper, 15 14 13 12 11 21 22 23 24 25	GBR + HA Coated Implant
Case 7	Female, 61y	Low, 42 41 31 32	Distraction HA Coated Implant
Case 8	Male, 58y	Upper,	Bone Harvest from The Tibia for Sinus Lifting & PRP

**\* Dembone+OsteoGen+ Bone**

Hounsfield Number		
Case 1	* →437	Upper, Left, 25
Case 2	280→407	Upper, Right, 16 ( without PRP ) Upper, Left, 26 ( with PRP )
Case 3	483→539	Upper, Right, 13, with PRP 4 Month→3 Months
Case 4	187.2→500 →790.3	Upper, Left, 12 without PRP →Upper, Left, 12 with PRP
Case 5	284→431	Upper, Left, 26 without PRP →Upper, Left, 22 with PRP
Case 6	530→712	Upper, with PRP→ 3 months with implant and PRP
Case 7	388.4→591.3	Pre Operation→ One Year After with PRP
Case 8	* →365.1	Pre Operation→ 3 Weeks with PRP



In the past, PRP had been considered no more than stimulating and accelerating the process of healing wounded soft tissue. It was not certain that it could serve as an effective inducer of bone tissue repair. Marx et al. (1998) demonstrated the efficacy of PRP in enhancing growth factors for bone grafts. Since then, studies of how to produce PRP effectively have been made to harvest lots of growth factors (PDGF, TGF- $\beta$ , VEGF, EGF and IGF-II) from autologous blood. The Smart PRP™ device used in our study had already yielded excellent results. In all of the three patients who participated in the present study, wound healing was promoted and accelerated. They did not develop any infectious diseases. The CT values increased from 120 to 203. Bone quality showed a tendency to improve.

Conclusion:

Compared with the conventional bone reconstruction method, the new treatment using PRP could be done with less surgical invasion and can be expected to improve the quality of bone. Thus, our findings suggested that the clinical application of PRP to enhance bone regeneration would be extended. At the same time, a big challenge for human beings to seek for the anti-aging and eternal esthetic beauty would be possibly fulfilled with the application of PRP.